

How compression of tubular bandage could be of assistance in 6-year-old venous ulcers

Marie Backeberg, Bcur I et A
Wound Care Professional
marie.backeberg@gmail.com

© Medpharm

Prof Nurs Today 2016;20(3):22-23

In wound care, the management of leg ulcers requires that the clinician must always consider a venous, arterial or mixed aetiology. Most wound care practitioners are also familiar with the ever present challenge of patients who need to wear compression, but are non-adherent. A common belief in the community and even among clinicians is that patients with leg ulcers need to wear "tight stockings" for optimal healing of wounds, without taking the vascular status into consideration.

Background

A 79-year-old female was admitted to hospital. The patient had venous ulcers on the medial and lateral malleoli of the left lower leg for at least 6 years. She had severe oedema of her left leg. There was no history of chronic illnesses or diabetes, but there was an allergy to silver. A medical provider asked her not to expect treatment, if she was not prepared to wear compression bandages. According to the patient any tight bandage and/or stocking caused excruciating pain in the leg.

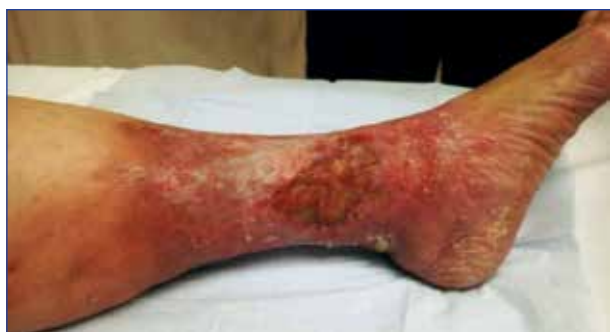

Photo by family before hospitalisation. Visible hyperpigmentation, inflammation and inverted champagne bottle shaped legs

Clinical examination

The vascular surgeon assessed the patient and confirmed that the femoral pulses were palpable, but not the popliteal or pedal pulses. Varicose veins with reflux and chronic venous incompetence were clinically diagnosed.

Duplex Doppler

Atherosclerosis was demonstrated with triphasic flow up to the popliteal artery. Severe calcification was demonstrated in the tibial arteries. Reflux was demonstrated in the vena saphena magna without any deep venous reflux.

Diagnosis Mixed venous and arterial ulcer

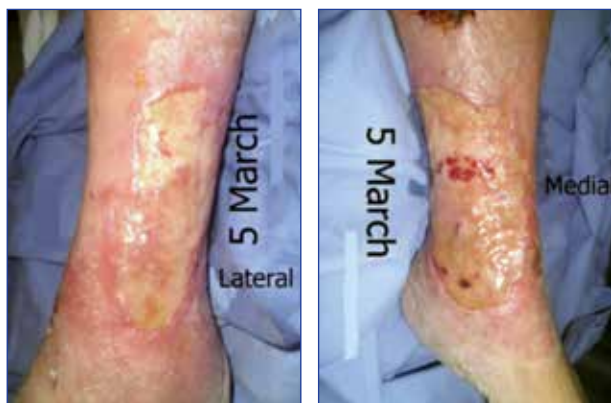Aim: To treat the underlying aetiological factors, starting with improved arterial supply to promote wound healing. To reduce oedema. To do a skin graft as soon as the wound beds were clean to minimize the length of treatment.

In patients presenting with mixed ulcers, compression therapy is only indicated after formal vascular assessment, and then only "appropriate modified compression therapy"¹ should be considered.

Method: The vascular surgeon performed an arteriogram with balloon angioplasty, which resulted in increased arterial flow to the ankle and collateral flow to the foot. Varicose vein stripping was also done. Wound care treatment concentrated on wound bed preparation for skin graft.

Suggested treatment

Cleaning with polyhexanide and betaine solution, dressed with polyhexanide gel, covered with hydrophobic gauze dressing, cotton bandage and softly applied crepe bandage. Patient was discharged from hospital with the agreement to

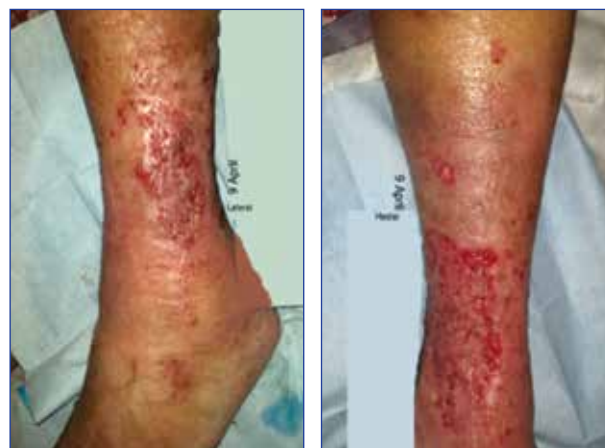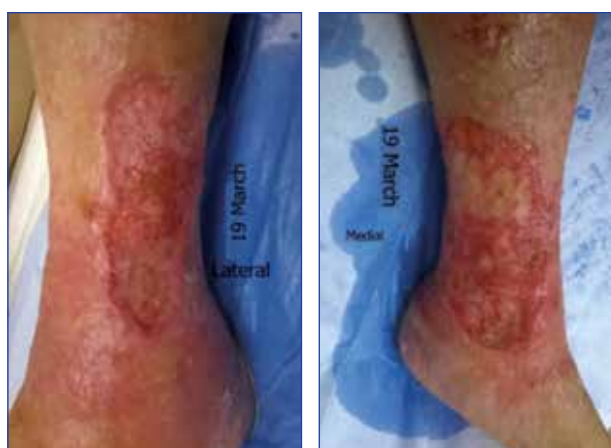


Photos taken in hospital: Slough on wound areas, with excessive serous exudate through the bandages

travel from her hometown to the consulted wound clinician at least twice a week for wound care.

- First visit to wound clinic: ABPI 1.05
- Leg measurements: Ankle: 25.5 cm
- Calf: 40 cm
- Wound size: Medial: 12 x 9 cm
- Lateral: 10 x 5 cm

The wounds started granulating, but remained severely oedematous. Since this patient had previous experience of severe leg pain when any tight-fitting bandages were applied, she was very hesitant for compression to be applied. The significance of oedema was explained to the patient. She agreed to cotton bandaging and tubular bandage on her leg, which was seen by the wound care practitioner as a starting option towards the application of compression or stockings. This at least, applied some compression, rather than no compression. She reported at her next visit that she had become used to the bandages and found them comfortable, but was not yet prepared to have compression applied.



Two weeks after wound treatment was started, good granulation could be seen in the wound beds, oedema reduced to the extent that skin graft could be planned, and was done one week after date per photos.

Leg measurements:

- Ankle: 24 cm
- Calf: 39 cm.

The patient still wore her tubular bandage after the skin grafting and then consented to stockings as prescribed. Leg measurements taken at follow up two weeks after skin graft:

- Ankle: 22 cm
- Calf: 38 cm

The vascular surgeon confirmed that a grade 2 stocking could be worn thereafter.

Conclusion

Compression with tubular bandage of about 7-8 mmHg is more effective than no compression to minimize oedema.²

References

1. WHASA Consensus document on the management of lower limb ulcers. South Africa. 2015. Volume 8 no 1. P4
2. Wound Healing Association of South Africa: 4th Interdisciplinary Conference on Wound care. Interactive sessions on Lower leg ulcers and Diabetic foot. 2015.
3. Mulder M, Small N, Botha Y, Zidy L, Mackenzie J. Basic Principles of Wound Care. Cape Town: Maskew Miller Longman. 2002.
4. Wounds International: Principles of compression in venous disease: a practitioner's guide to treatment and prevention of venous leg ulcers. Wounds International, 2013. Available from: www.woundinternational.com